



**Realización de un conducto ilíaco
sin anastomosis distal para
procedimientos endovasculares:
una manera corta de hacer un
conducto ilíaco para
procedimientos endovasculares**

**Iliac conduit for endovascular
treatment without distal
anastomosis: a short way to make
an iliac conduit for endovascular
procedures**

10.20960/angiologia.00728

02/28/2025

Iliac conduit for endovascular treatment without distal anastomosis: a short way to make an iliac conduit for endovascular procedures

Realización de un conducto ilíaco sin anastomosis distal para procedimientos endovasculares: una manera corta de hacer un conducto ilíaco para procedimientos endovasculares

René Romero Sarmiento, Ignacio Michel Guisasola, José A. González-Fajardo

Angiology, Vascular Surgery and Endovascular Department. Hospital Universitario 12 de Octubre. Madrid, Spain

Correspondence: René Romero Sarmiento. Angiology, Vascular Surgery and Endovascular Department. Hospital Universitario 12 de Octubre. Avda. de Córdoba, s/n. 28041 Madrid, Spain

e-mail: reneromero1991@hotmail.com

Received: 1/13/2025

Accepted: 1/13/2025

Conflicts of interest: the authors declared no conflicts of interest.

Artificial intelligence: the authors declare that they did not used any artificial intelligence (AI) or AI-assisted technologies to write this the article.

ABSTRACT

The iliac conduit technique without distal anastomosis has emerged as an effective solution for managing challenging vascular access during complex endovascular procedures, particularly in patients with small, calcified, or diseased femoral arteries. This article discusses the clinical indications, advantages, and key surgical steps for performing an iliac conduit procedure in a short way: easy, quickly and safe.

Keywords: Iliac. Conduit. Endovascular. Without. Distal. Anastomosis.

RESUMEN

La técnica del conducto ilíaco sin anastomosis distal ha surgido como una solución eficaz para el manejo de accesos vasculares difíciles durante procedimientos endovasculares complejos, en particular en pacientes con arterias femorales pequeñas, calcificadas o enfermas. En este artículo se analizan las indicaciones clínicas, las ventajas y los pasos quirúrgicos claves para realizar un procedimiento que nos permita tener un buen acceso ilíaco de manera fácil, rápida y segura.

Palabras clave: Ilíaco. Conducto. Endovascular. Sin. Distal. Anastomosis.

INTRODUCTION

Endovascular techniques, such as endovascular aortic repair (EVAR) and thoracic endovascular aortic repair (TEVAR), often require large-bore vascular access. In patients with small, calcified, or diseased femoral arteries, traditional femoral access becomes infeasible. In these cases, the iliac conduit offers a viable alternative. The modification of omitting the distal anastomosis in the first stage simplifies the procedure further and ensures a safer, faster approach with improved outcomes. We describe this technique to optimize the approach for challenging vascular access.

INDICATIONS

The iliac conduit technique is indicated when the native iliac artery cannot accommodate the endovascular device due to size, calcification, or stenosis. Common clinical scenarios include:

1. Large-caliber prosthesis requirements in EVAR or TEVAR procedures.

2. Aortoiliac occlusive disease where traditional access is not feasible.
3. Hostile groin anatomy, such as prior surgeries, radiation damage, or extensive scar tissue.

Avoiding the femoral artery, this approach mitigates complications in patients who are at higher surgical risk.

ADVANTAGES OF THE ILIAC CONDUIT WITHOUT DISTAL ANASTOMOSIS

The iliac conduit without distal anastomosis, performed as a first step, offers several significant advantages over traditional femoral access or standard iliac conduit procedures:

1. *Reduced Operative Time:* omitting the distal anastomosis eliminates the need for extensive suturing, streamlining the surgical process.
2. *Avoidance of Groin Incision and Dissection:* by not accessing the femoral artery, the groin remains untouched, reducing the risk of surgical site infections, particularly in high-risk patients.
3. *Simplified Access for Future Interventions:* if re-intervention were required, the iliac conduit can be ligated distally and advanced to the inguinal ligament. This facilitates subsequent endovascular access through a simple groin incision.
4. *Lower Risk of Complications:* by reducing the operative exposure and bypassing the femoral artery, the likelihood of hematoma, infection, and groin wound complications is minimized.

SURGICAL TECHNIQUE

A/ First Stage:

1. *Preoperative Planning:* It is essential to have a preoperative image (angio-CT) to assess the iliac anatomy, vessel caliber

and pathology. We need to select an appropriate conduit material (Dacron 10mm).

2. *Exposure of the Common Iliac Artery:* We perform a standard retroperitoneal approach to exposure to expose the common iliac artery with careful dissection to minimize injury to surrounding structures.
3. *Proximal Anastomosis:* After systemic heparinization and clamping, we perform an end-to-side anastomosis of the conduit to the common iliac artery. This is the only anastomosis required (Fig. 1).
4. *To place the conduit subcutaneously at the inguinal level:* The conduit is placed straight on in the subcutaneous at the inguinal level. We ensure the hemostasis and patency. Finally, the end is ligated and sutured (prolene 5/0) to prevent bleeding (Fig. 2).

B/ Second Stage:

1. *Conduit Management:* Several days afterwards, we look for the prosthesis subcutaneously at the inguinal level. It is easy because it has not been yet integrated. Logically, the conduit is thrombosed, but by manual thrombectomy with a Fogarty catheter the prosthesis is reopened, and it can be used as an access point for introducing endovascular devices (Fig. 3).

When we finish the procedure, the conduit is again distally ligated, sutured and placed subcutaneously. Finally, we closed the wound.

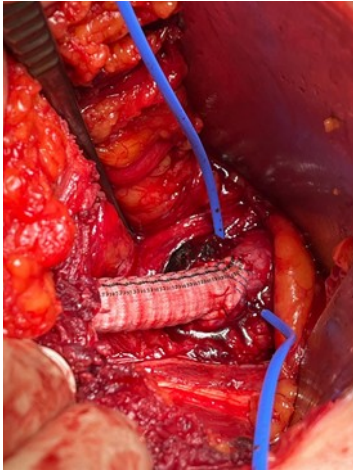


Figure 1. Proximal common iliac anastomosis by retroperitoneal approach.

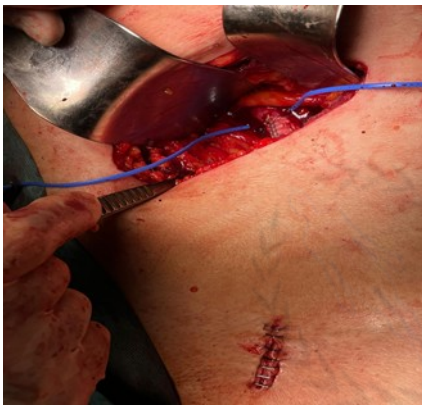


Figure 2. The Conduit is placed subcutaneously at the inguinal level by a small access.

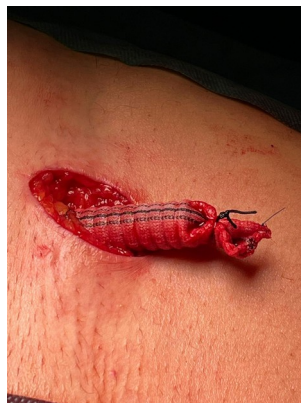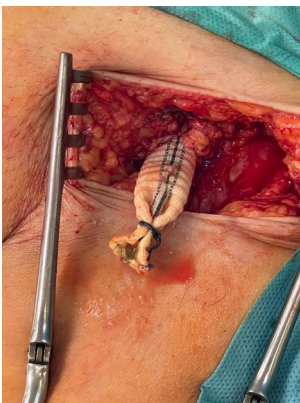


Figure 3. A. Several days afterwards, the conduit is localized in the inguinal area previously treated. B. By manual thrombectomy with a Fogarty catheter the prosthesis is re-opened.

DISCUSSION

The iliac conduit without distal anastomosis provides a safe and effective alternative for patients requiring large-bore vascular access but presenting with difficult anatomy or significant comorbidities. This modification reduces operative time, avoids unnecessary groin complications, and streamlines management of future interventions. Our experience has demonstrated favorable outcomes with this approach, particularly in high-risk patients undergoing EVAR and TEVAR procedures.

CONCLUSIONS

The iliac conduit without distal anastomosis as a first step represents a significant advancement in endovascular treatment, particularly for patients with limited vascular access options. By simplifying the conduit creation process and eliminating the need for extensive distal suturing, this technique improves procedural efficiency, reduces operative risk, and enhances patient outcomes.

Further studies and long-term follow-up data will continue to validate its role in contemporary vascular surgery.

RECOMENDED REFERENCES

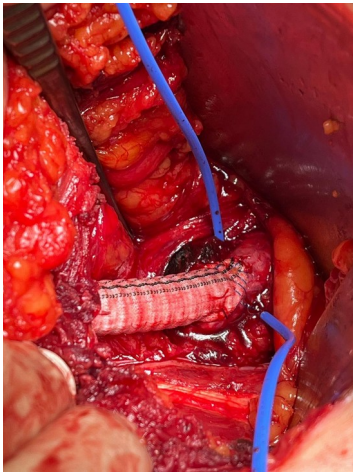
1. Chaudhuri A, Ark R. Innovations in Vascular Access: Iliac Conduit Techniques. *Seminars Vasc Surg* 2019;32(2):91-7.
2. Kouvelos GN, Koutsoumpelis A, Matsagkas M. Outcomes of Iliac Conduit Placement in EVAR. *Ann Vasc Surg* 2020;67:10-8.
3. Oderich GS, Ribeiro M, Hofer J. Techniques for Iliac Conduits in Endovascular Repair. *J Vasc Surg* 2017;66(3):835-44.

4. Veith FJ, et al. Optimizing Access for Complex EVAR Procedures: Iliac Conduits. Eur J Vasc Endovasc Surg 2018;55(4):537-45.



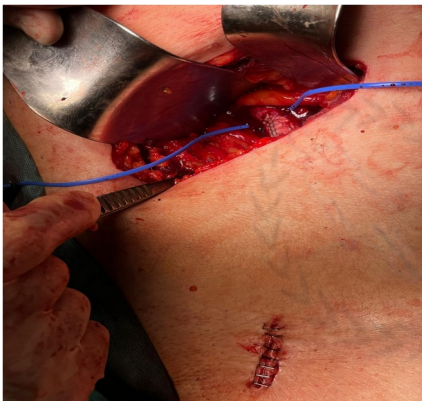
FIGURES AND LEGENDS.

Fig.1



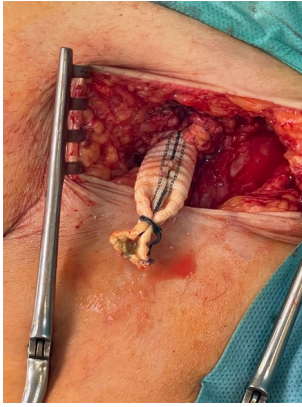
Proximal common iliac anastomosis by retroperitoneal approach.

Fig. 2

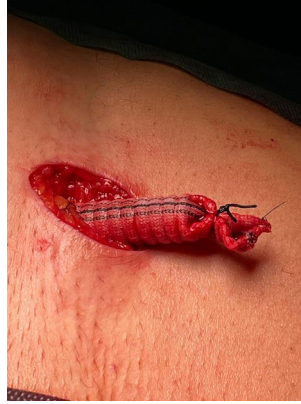

The Conduit is placed subcutaneously at the inguinal level by a small access.

Fig. 3



A



B

A/ Several days afterwards, the conduit is localized in the inguinal area previously treated. B/By manual thrombectomy with a Fogarty catheter the prosthesis is re-opened.

